

# THE MYSTERY OF THE HUNTER'S BUMP

by Judy Wardrope



Like so many other things equine, when it comes to the hunter's bump, there are no absolutes. Most of us recognize a hunter's bump – or jumper's bump, as it is sometimes called – when we see one, but ask horse people what it is, what causes it, if it's a fault or a blemish, and you will get a variety of answers. The responses vary from "I won't buy a horse with one; it's a weakness" to "I've had tons of horses with them without any problems." The responses usually depend on their personal experiences, but most say, "I don't know what causes them."

It's not just horse owners who disagree. Read the books on equine conformation and lameness or the results of veterinary studies, and you'll not only find differing opinions regarding the severity of the problem, you'll find a lack of agreement on the cause. They do agree that a hunter's bump can be painful while developing, that it generally, but not always, heals.

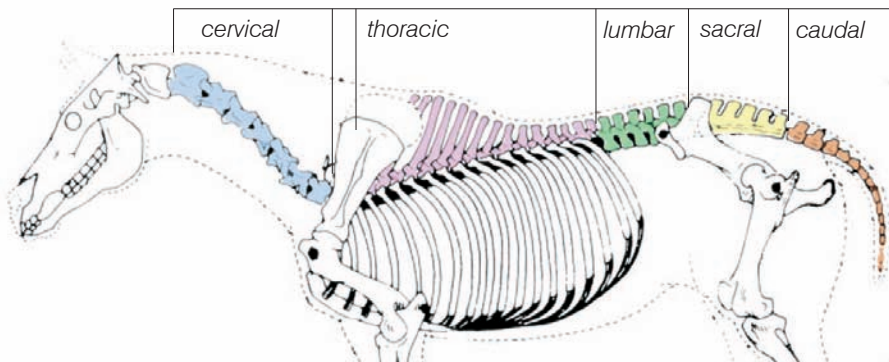
## An average spine?

Contributing to the mystery is the fact that the number of vertebrae in the five regions of the equine vertebral column vary. In Dr. G. Joe Mayhew's 1999 presentation, *The Healthy Spinal Cord*, the University of Edinburgh researcher stated that the generally accepted number of vertebrae are:

C (cervical) = 7, T (thoracic) = 18, L (lumbar) = 6, S (sacral) = 5, Ca (caudal, or the origins of the tail) = 15 – 21.

Of almost 100 domestic horses in his studies however, the following variances were found in the thoracic region: 17 T vertebrae were found in ten per cent, 19 in six per cent and 18.5 (the half indicating a transitional vertebra) in one per cent. That translates to 17 per cent of horses deviating from the norm.

Furthermore, in the lumbar region, three per cent of horses only had five L vertebrae and one per cent had five-and-a-half. The sacrum varied as well, with five per cent having four vertebrae, one per cent having four-and-a-half, one per cent hav-



The generally accepted number of vertebrae in the equine spine:  
 C (cervical) = 7, T (thoracic) = 18, L (lumbar) = 6, S (sacral) = 5, Ca (caudal, or the origins of the tail) = 15 – 21

ing five-and-a-half, and seven per cent having one or two fused Ca vertebral bodies forming the sacral plate.

With so much variety in the number of vertebrae in a horse's spine is it any wonder that there is such disagreement about the effects of a hunter's bump?

### Authoritative disagreements

**First opinion:** *Equine Research's Veterinary Treatments & Medications for Horsemen* states, "Dislocation of the articulation between the vertebral column and the pelvis occurs when the tuber sacrale (near the loin/croup junction) is pushed upward and forward because of torn ligament attachments, creating the hunter's bump (sacroiliac joint subluxation)."

**Second opinion:** In the revised edition of *The Lambe Horse*, Dr. James Rooney (DVM) defines a hunter's bump as an elevation of the tuber sacrale above the top line of the croup, which may be normal conformation or appear because of dislocation of the sacroiliac joint. He goes on to say, "It occurs most often in jumping horses, steeplechasers, hunters, and occasionally in runners used to pace Standardbreds in time trials ... In early stages one can, walking along behind the horse, see this bump, the upwardly displaced tuber sacrale, moving up and down. Soon that movement ceases, but the bump remains."

These two sources seem to consider 'hunter's bump' and 'sacroiliac joint subluxation' as interchangeable terms. Other sources and recent studies diverge from that standpoint, preferring to pronounce sacroiliac joint subluxation as the extreme and hunter's bumps as the result of milder injuries.

**Third opinion:** In the *Illustrated Atlas of Clinical Equine Anatomy and Common Disorders of the Horse*, Ronald J. Riegel (DVM) and Susan Hokala (BS, RN, CMI) state, "In almost all cases, the visualization of these prominences does not indicate an underlying sacroiliac problem. They do, however, occur or become visible when there is an atrophy of the musculature within this area. Infrared thermography allows a differentiation of hunter's bumps from sacroiliac problems. The amount of trauma that would be required to cause an instability within the sacroiliac joint can only be caused from a very bad fall or slip. Any widening of the sacroiliac joint space, or rotation of the pelvis or sacrum, is diagnostic for this condition."

The 2004 publication of *Functional Anatomy and Pathophysiology of Sacroiliac Joint Disease* by K.K Haussler from the College of Veterinary Medicine at Cornell University included an acknowledgment regarding the divergent opinions: "The sacroiliac joint region continues to be an area of confusion for most practitioners

## Risky business

A study by S. Dyson and R. Murray from the Centre for Equine Studies, Animal Health Trust, in Newmarket, UK, identified sacroiliac joint region disease in 74 horses between November 1997 and March 2002.

The publication of their findings states that dressage and show jumping horses appeared to be at particular risk. Affected horses were generally slightly older than the normal clinic population, taller at the withers, and of greater bodyweight.

There was a significant effect of breed, with a substantially higher proportion of Warmblood horses (51 per cent) in the SI (sacroiliac) pain group compared to the normal clinic population (29 per cent).

There was no correlation between conformation and the presence of sacroiliac joint region pain. The tubera sacrale appeared grossly symmetrical in most (95 per cent) horses.

Poor development of the epaxial muscles in the thoracolumbar region and asymmetry of the hindquarter musculature were common. Twenty-six horses (35 per cent) showed restricted flexibility of the thoracolumbar region and 10 (16 per cent) had an exaggerated response to pressure applied over the tubera sacrale. Fourteen horses (19 per cent) were reluctant to stand on one hindlimb for prolonged periods.

The majority of horses (75 per cent) had a straight hindlimb flight and only 18% moved closely behind or plaited. In all horses, restricted hindlimb impulsion was the predominant feature; invariably this was most obvious when the horse was ridden. Stiffness, unwillingness to work on the bit and poor quality canter were common. Sacroiliac joint region pain was seen alone (47 per cent), or in conjunction with thoracolumbar pain (16 per cent), hindlimb lameness (20 per cent), forelimb lameness (7 per cent) or a combination of problems (10 per cent).

Seventy-three horses (99 per cent) had abnormalities of the sacroiliac joint region identified using nuclear scintigraphy.

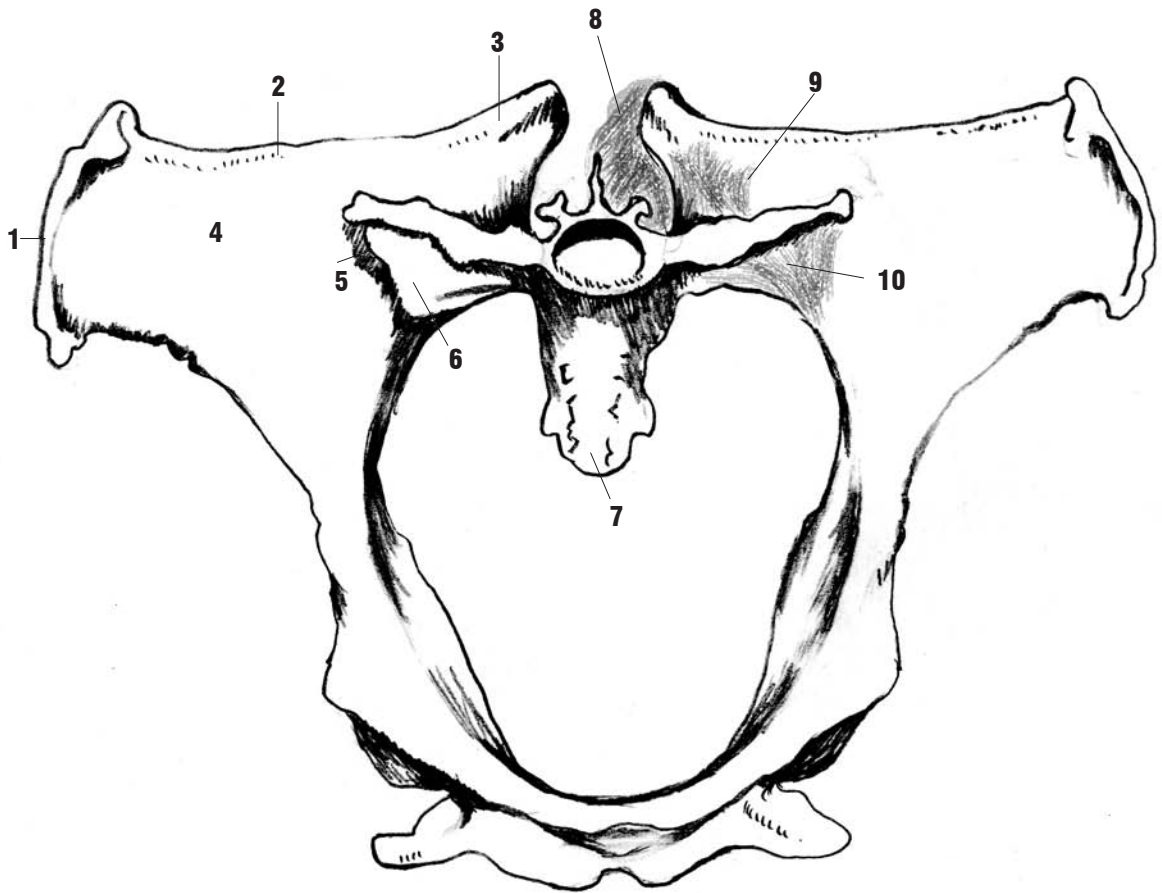


Diagram of the pelvis, sacrum, and sacroiliac ligaments (cranial view). (1) Tuber coxae, (2) ilial crest, (3) tuber sacrale, (4) ventral surface of the iliac wing, (5) sacroiliac articulation, (6) sacral wing, (7) sacrum, (8) dorsal sacroiliac ligament, (9) interosseous sacroiliac ligament, (10) ventral sacroiliac ligament. (Reprinted from Haussler KK. *Diagnosis and management of sacroiliac joint injuries*. In: Ross MW, Dyson SJ, eds. *Diagnosis and management of lameness in the horse*. St. Louis, MO: WB Saunders, 2003; 501-508.)

because of its deep location and unique anatomic features. Additionally, there have been a limited number of biomechanical investigations into its functional significance.”

Haussler also said that the presumed diagnosis of sacroiliac joint subluxation based solely on the presence of tuber sacrale height asymmetry (hunter’s bump) is inappropriate. “Variable degrees of tuber sacrale height asymmetry occur frequently, [and can be] expected because of the extension of the lumbosacral joint that occurs during lift-off when jumping or when pressure is applied to the sacrum [such as] during a fall.

Horses with chronic sacroiliac problems and presumed sacroiliac joint subluxation have not had identifiable changes in the sacroiliac ligaments at necropsy.

In addition, Standardbred trotters with substantial tuber sacrale height asymmetries did not have significant increases in sacroiliac pain compared with horses with lesser degrees of asymmetry. Tuber sacrale height asymmetries are also common in horses without documented sacroiliac joint injuries. Tuber sacrale height asymmetries have been associated with chronic sacroiliac ligament injuries or joint laxity in only a few horses.”

### Personal observations

Beyond what Nancy Loving (DVM) says in *Conformation and Performance* regarding horses with a weak loin or long back being prone to developing hunter’s bumps, I have found that those with a lumbosacral junction (LS) back of the point of hip are at the most risk. I’ve noticed too that pronounced hunter’s

bumps are a rarity in upper level horses in jumping, eventing and dressage. Horses in this latter group invariably have an LS over the point of hip.

### Prevention and treatment

Loving suggests that adequate conditioning of back, abdominal and haunch muscles help prevent strain. Rooney says, “Avoid fatigue, keep the horse and rider weight under control. There is no treatment. The condition will stabilize with time – variable from horse to horse – and work may resume. Some horses return to full jumping work at their previous competitive level, but most have a residual limitation or change of movement of the affected leg; they can work but at reduced class.”

